CHAPTER 5

Tissues

Understanding Words

adip-, fat: *adipose* tissue—tissue that stores fat.

chondr-, cartilage: *chondrocyte*—cartilage cell.

-cyt, cell: osteo*cyte*—bone cell.

epi-, upon, after, in addition: *epi*thelial tissue—tissue that covers all free body surfaces.

-glia, glue: neuro*glia*—cells that support neurons; part of nervous tissue.

hist-, web, tissue: *hist*ology—study of composition and function of tissues.

hyal-, resemblance to glass: *hyal*ine cartilage—flexible tissue containing chondrocytes.

inter-, among, between: *inter*calated disc—band between adjacent cardiac muscle cells.

macr-, large: *macro*phage—large phagocytic cell.

neur-, nerve: *neuro*n—nerve cell.

os-, bone: *os*seous tissue—bone tissue.

phag-, to eat: *phag*ocyte—cell that engulfs and destroys foreign particles.

pseud-, false: *pseud*ostratified epithelium—tissue with cells that appear to be in layers, but are not.

squam-, scale: *squam*ous epithelium—tissue with flattened or scalelike cells.

strat-, layer: *strat*ified epithelium—tissue with cells that are in layers.

stria-, groove: *stria*ted muscle—tissue whose cells have alternating light and dark cross-markings.

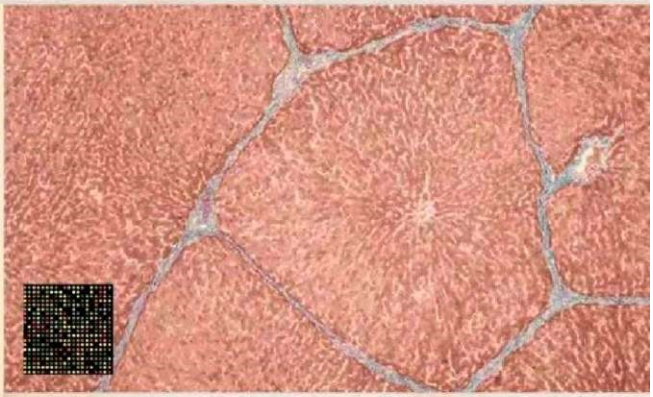

Two views of tissues. Traditional microscopy (a) provides structural looks at tissues. DNA microarrays (b) provide functional views.

Chapter Objectives

After you have studied this chapter, you should be able to

1. Describe the general characteristics and functions of epithelial tissue.
2. Name the types of epithelium and identify an organ in which each is found.
3. Explain how glands are classified.
4. Describe the general characteristics of connective tissue.
5. Describe the major cell types and fibers of connective tissue.
6. List the types of connective tissue.
7. Describe the major functions of each type of connective tissue.
8. Describe the four major types of membranes.
9. Distinguish among the three types of muscle tissue.
10. Describe the general characteristics and functions of nervous tissue.

A tissue atlas typically displays groups of cells stained to reveal their specializations and viewed with the aid of a microscope. It's easy to tell skeletal muscle from adipose tissue from blood. A new way to look at tissues, though, is to profile the proteins that their cells manufacture, which are ultimately responsible for their specialized characteristics. These characteristics arise from the expression of subsets of the genome. For example, a skeletal muscle cell transcribes messenger RNA molecules from genes that encode contractile proteins, whereas an adipose cell yields mRNAs whose protein products enable the cell to store massive amounts of fat. All cells also transcribe many mRNAs whose encoded proteins make life at the cellular level possible.

In the mid 1990s, technology was developed to display the genes that are expressed in particular cell types. The tool is a DNA microarray (also known as a gene chip). It is a square of glass or plastic smaller than a postage stamp to which thousands of small pieces of DNA of known sequence are bound, in a grid pattern, so that the position of each entrant is known. Then mRNAs are extracted from a cell or tissue sample, converted to DNA "probes," and labeled with a fluorescent dye. The grid positions where the probes bind fluoresce, which a laser scanner detects and converts to an image; the intensity of the fluorescence can reveal how abundant the represented mRNA is. Probes representing two cell sources can be linked to different fluorescent tags so that their gene expression patterns can be directly compared—such as a healthy and cancerous version of the same cell type. Now that the human genome has been sequenced, a microarray can scan for activity in all genes. Alternatively, microarrays can be customized to paint molecular portraits of specific functions.

DNA microarrays were first used to distinguish subtypes of cancers whose cells look identical under a microscope, but differ in their physiology. For example, some patients with a particular type of leukemia who did not respond to conventional drugs actually had a different type of the blood cancer—revealed only in the DNA microarray. With a different treatment, they are more likely to survive.

Researchers are compiling DNA microarray patterns for the 260° types of normal differentiated cells in a human body. A statistical analysis called hierarchy clustering groups cells by similarities in gene expression. The results generally agree with what is known of histology (the study of tissues) from microscopy, but go farther. For example, in one experiment that probed 35 tissue types for the activity of 26,000 genes, the cells of various lymphoid tissues (tonsils, thymus, and spleen) had very similar gene expression profiles, as did the organs of the digestive system. A liver cell expressed genes that encode clotting factors, transporters of metals and lipids, and enzymes involved in detoxification and metabolism—all logical. But the microarray also revealed activity of four proteins whose roles in liver function are unknown.

Traditional tissue atlases reveal what we can see; DNA microarrays reveal what we cannot. This new approach will not only provide baseline portraits of cells to which injured or diseased counterparts can be compared, but will reveal new points of therapeutic intervention. For example, DNA microarrays identified proteins synthesized just after a spinal cord injury that were previously known to be produced only after injury to the deep layer of the skin. This unexpected finding suggests new points for drugs, perhaps even existing ones, to intervene. ■

In all complex organisms, cells are organized into **tissues,** which are layers or groups of similar cells with a common function. Tissues can be distinguished from each other by variations in cell size, shape, organization, and function. The study of tissues, **histology,** will assist understanding in later discussions of the physiology of organs and organ systems.

The tissues of the human body include four major types: *epithelial, connective, muscle,* and *nervous.* These tissues associate and interact to form organs that have specialized functions. Table 5.1 compares the four major tissue types.

This chapter examines in detail epithelial and connective tissues, and provides an introduction to muscle and nervous tissues. Throughout this chapter, simplified line drawings (for example, fig. 5.1*a*) are included with each micrograph (for example, fig. 5.1*b*) to emphasize the distinguishing characteristics of the specific tissue, as well as a locator icon (an example of where in the body that particular tissue may be found). Chapter 9 discusses muscle tissue in more detail, and chapters 10 and 11 detail nervous tissue.

1 What is a tissue?

2 List the four major types of tissue.

Epithelial Tissues

General Characteristics

Epithelial tissues (ep″ĭ-the′le-al tish′ûz) are found throughout the body. Because epithelium covers the body surface and organs, forms the inner lining of body cavities, and lines hollow organs, it always has a *free (apical) surface*—one that is exposed to the outside or to an open space internally. The underside of this tissue is anchored to connective tissue by a thin, nonliving layer called the **basement membrane.**

TABLE 5.1 Tissues

Type	Function	Location	Distinguishing Characteristics
Epithelial	Protection, secretion, absorption, excretion	Cover body surface, cover and line internal organs, compose glands	Lack blood vessels, cells readily divide, cells are tightly packed
Connective	Bind, support, protect, fill spaces, store fat, produce blood cells	Widely distributed throughout the body	Mostly have good blood supply, cells are farther apart than epithelial cells, with extracellular matrix in between
Muscle	Movement	Attached to bones, in the walls of hollow internal organs, heart	Able to contract in response to specific stimuli
Nervous	Transmit impulses for coordination, regulation, integration, and sensory reception	Brain, spinal cord, nerves	Cells communicate with each other and other body parts

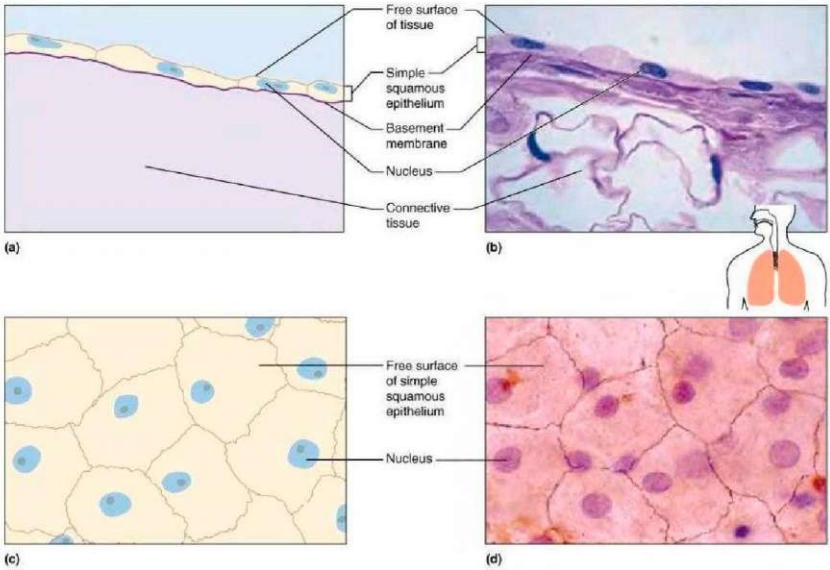

FIGURE 5.1
Simple squamous epithelium consists of a single layer of tightly packed, flattened cells (670×). (*a*) and (*b*) side view, (*c*) and (*d*) surface view.

One of the ways that cancer cells spread is by secreting a substance that dissolves basement membranes. This enables cancer cells to invade adjacent tissue layers. Cancer cells also produce fewer adhesion proteins, or none at all, which allows them to invade surrounding tissue.

As a rule, epithelial tissues lack blood vessels. However, nutrients diffuse to epithelium from underlying connective tissues, which have abundant blood vessels.

Because epithelial cells readily divide, injuries heal rapidly as new cells replace lost or damaged ones. Skin cells and the cells that line the stomach and intestines are epithelial cells that are continually being damaged and replaced.

Epithelial cells are tightly packed. In many places, desmosomes attach one to another, enabling these cells to form effective protective barriers in such structures as the outer layer of the skin and the inner lining of the mouth. Other epithelial functions include secretion, absorption, and excretion.

RECONNECT TO CHAPTER 3, INTERCELLULAR JUNCTIONS, PAGE 80.

Epithelial tissues are classified according to the shape and number of layers of cells. Epithelial tissues that are composed of thin, flattened cells are *squamous;* those with cubelike cells are *cuboidal;* and those with elongated cells are *columnar;* those with single layers of cells are *simple;* those with two or more layers of cells are *stratified.* In the following descriptions, note that modifications of the free surfaces of epithelial cells reflect their specialized functions.

1 List the general characteristics of epithelial tissue.

2 Explain how epithelial tissues are classified.

Simple Squamous Epithelium

Simple squamous (skwa'mus) **epithelium** consists of a single layer of thin, flattened cells. These cells fit tightly together, somewhat like floor tiles, and their nuclei are usually broad and thin (fig. 5.1).

Substances pass rather easily through simple squamous epithelium, which is common at sites of diffusion and filtration. For instance, simple squamous epithelium lines the air sacs (alveoli) of the lungs where oxygen and carbon dioxide are exchanged. It also forms the walls of capillaries, lines the insides of blood and lymph vessels, and covers the membranes that line body cavities. However, because it is so thin and delicate, simple squamous epithelium is easily damaged.

Simple Cuboidal Epithelium

Simple cuboidal epithelium consists of a single layer of cube-shaped cells. These cells usually have centrally located, spherical nuclei (fig. 5.2).

Simple cuboidal epithelium lines the follicles of the thyroid gland, covers the ovaries, and lines the kidney tubules and ducts of certain glands—such as the salivary glands, pancreas, and liver. In the kidneys, it functions in tubular secretion and tubular reabsorption; in glands, it secretes glandular products.

Simple Columnar Epithelium

Simple columnar epithelium is composed of a single layer of elongated cells whose nuclei are usually at about the same level, near the basement membrane (fig. 5.3). The cells of this tissue can be ciliated or nonciliated. *Cilia,* which are 7–10 μm in length, extend from the free surfaces of the cells, and they move constantly. In the female, cilia aid in moving the egg cell through the uterine tube to the uterus.

Nonciliated simple columnar epithelium lines the uterus and portions of the digestive tract, including the stomach and small and large intestines. Because its cells are elongated, this tissue is thick, which enables it to protect underlying tissues. Simple columnar epithelium also secretes digestive fluids and absorbs nutrients from digested food.

Simple columnar cells, specialized for absorption, often have many tiny, cylindrical processes extending from their free surfaces. These processes, called *microvilli,* are from 0.5 to 1.0 μm long. They increase the surface area of the cell membrane where it is exposed to substances being absorbed (fig. 5.4).

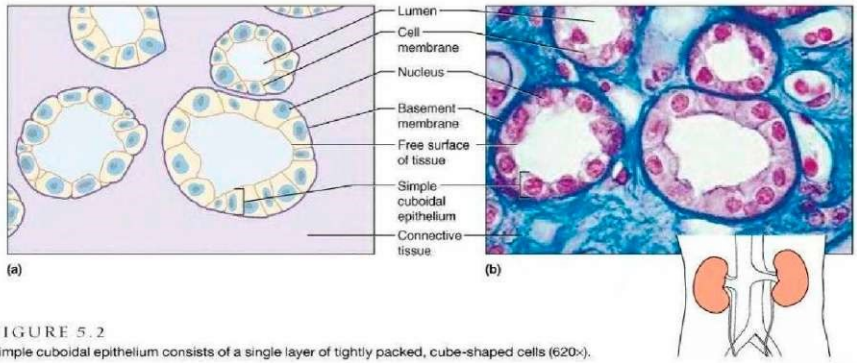

FIGURE 5.2
Simple cuboidal epithelium consists of a single layer of tightly packed, cube-shaped cells (620×).

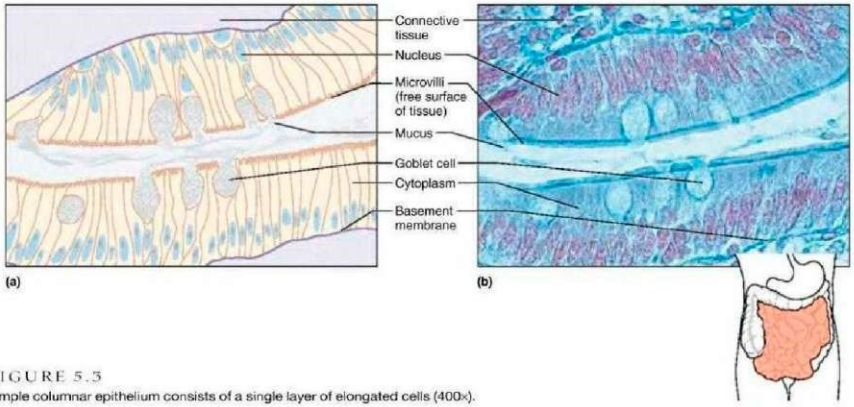

FIGURE 5.3
Simple columnar epithelium consists of a single layer of elongated cells (400×).

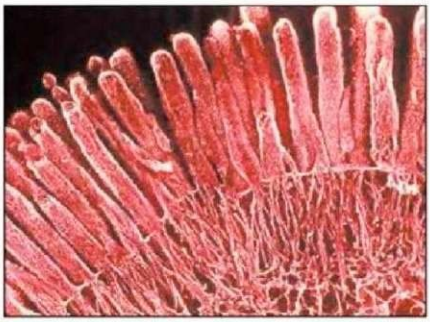

FIGURE 5.4
A scanning electron micrograph of microvilli, which fringe the free surfaces of some columnar epithelial cells (33,000×).

Typically, specialized, flask-shaped glandular cells are scattered among the cells of simple columnar epithelium. These cells, called *goblet cells*, secrete a protective fluid called *mucus* onto the free surface of the tissue (see fig. 5.3).

Pseudostratified Columnar Epithelium

The cells of **pseudostratified** (soo"do-strat'ĭ-fīd) **columnar epithelium** appear stratified or layered, but they are not. A layered effect occurs because the nuclei are at two or more levels in the row of aligned cells. However, the cells, which vary in shape, all reach the basement membrane, even though some of them may not contact the free surface.

Pseudostratified columnar epithelial cells commonly have cilia, which extend from the free surfaces of the cells. Goblet cells scattered throughout this tissue secrete mucus, which the cilia sweep away (fig. 5.5).

Pseudostratified columnar epithelium lines the passages of the respiratory system. Here, the mucous-covered linings are sticky and trap dust and microorganisms that enter with the air. The cilia move the mucus and its captured particles upward and out of the airways.

Stratified Squamous Epithelium

Stratified epithelium is named for the shape of the cells forming the outermost layers. **Stratified squamous epithelium** consists of many layers of cells, making this tissue relatively thick. Cells nearest the free surface are flattened the most, whereas those in the deeper layers, where cell division occurs, are cuboidal or columnar. As the newer cells grow, older ones are pushed farther and farther outward, where they flatten (fig. 5.6).

The outermost layer of the skin (epidermis) is stratified squamous epithelium. As the older cells are pushed outward, they accumulate a protein called *keratin*, then harden and die. This "keratinization" produces a covering of dry, tough, protective material that prevents water and other substances from escaping from underlying tissues and blocks chemicals and microorganisms from entering.

Stratified squamous epithelium also lines the oral cavity, esophagus, vagina, and anal canal. In these parts, the tissue is not keratinized; it stays soft and moist, and the cells on its free surfaces remain alive.

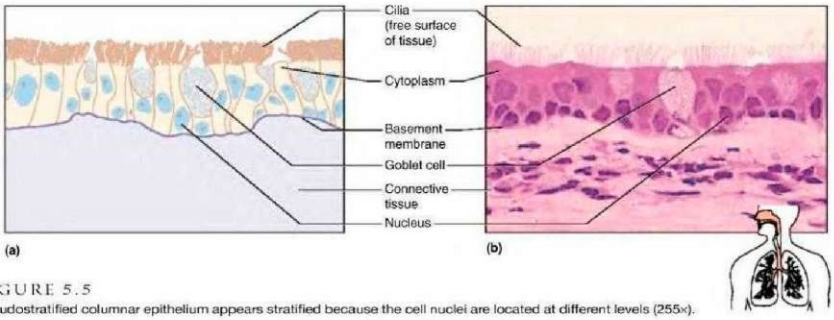

FIGURE 5.5
Pseudostratified columnar epithelium appears stratified because the cell nuclei are located at different levels (255×).

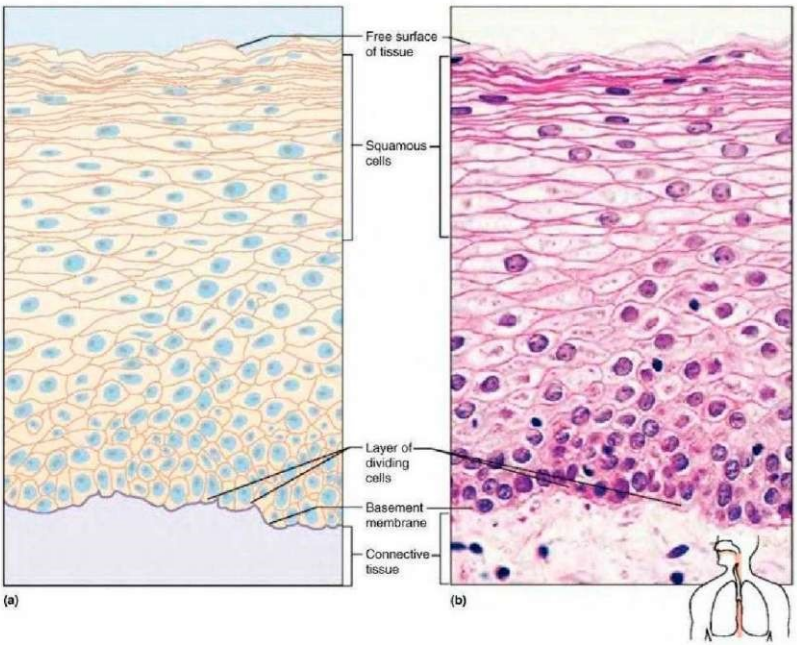

FIGURE 5.6
Stratified squamous epithelium consists of many layers of cells (385×).

Stratified Cuboidal Epithelium

Stratified cuboidal epithelium consists of two or three layers of cuboidal cells that form the lining of a lumen (fig. 5.7). The layering of the cells provides more protection than the single layer affords.

Stratified cuboidal epithelium lines the larger ducts of the mammary glands, sweat glands, salivary glands, and pancreas. It also forms the lining of developing ovarian follicles and seminiferous tubules, which are parts of the female and male reproductive systems, respectively.

Stratified Columnar Epithelium

Stratified columnar epithelium consists of several layers of cells (fig. 5.8). The superficial cells are elongated, whereas the basal layers consist of cube-shaped cells. Stratified columnar epithelium is found in part of the male urethra and in parts of the pharynx.

Transitional Epithelium

Transitional epithelium (uroepithelium) is specialized to change in response to increased tension. It forms the inner lining of the urinary bladder and lines the ureters and part of the urethra. When the wall of one of these organs contracts, the tissue consists of several layers of cuboidal cells; however, when the organ is distended, the tissue stretches, and the physical relationships among the cells change. While distended, the tissue appears to contain only a few layers of cells (fig. 5.9). In addition to providing an expandable lining, transitional epithelium forms a barrier that helps prevent the contents of the urinary tract from diffusing back into the internal environment.

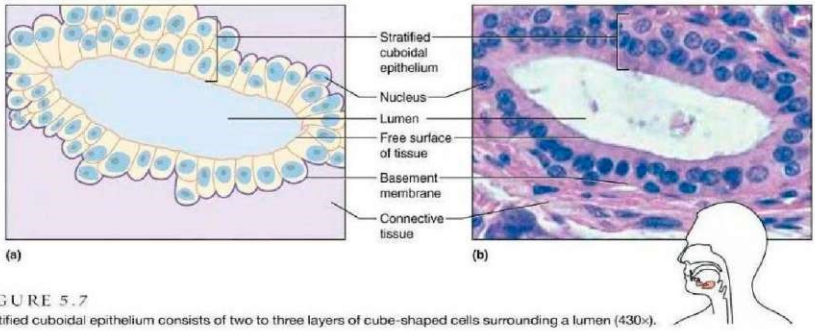

FIGURE 5.7
Stratified cuboidal epithelium consists of two to three layers of cube-shaped cells surrounding a lumen (430×).

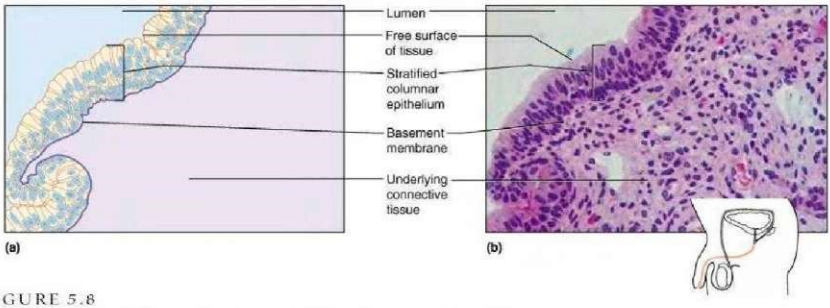

FIGURE 5.8
Stratified columnar epithelium consists of a superficial layer of columnar cells overlying several layers of cuboidal cells (220×).

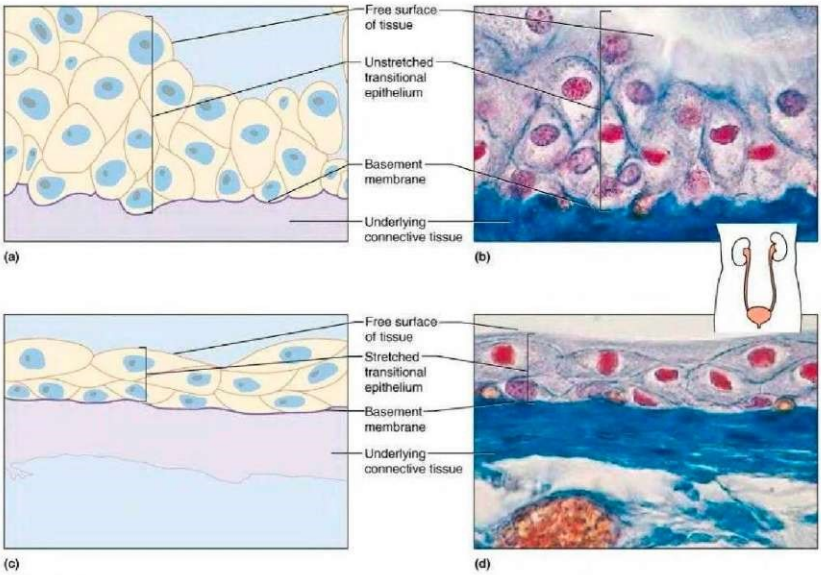

FIGURE 5.9
Transitional epithelium. (*a* and *b*) When the organ wall contracts, transitional epithelium is unstretched and consists of many layers (675×). (*c* and *d*) When the organ is distended, the tissue stretches and appears thinner (675×).

> Up to 90% of all human cancers are *carcinomas*, which are growths that originate in epithelium. Most carcinomas begin on surfaces that contact the external environment, such as skin, linings of the airways in the respiratory tract, or linings of the stomach or intestines in the digestive tract. This observation suggests that the more common cancer-causing agents may not penetrate tissues very deeply.

1 Describe the structure of each type of epithelium.

2 Describe the special functions of each type of epithelium.

Glandular Epithelium

Glandular epithelium is composed of cells that are specialized to produce and secrete substances into ducts or into body fluids. Such cells are usually found within columnar or cuboidal epithelium, and one or more of these cells constitutes a *gland*. Glands that secrete their products into ducts that open onto surfaces, such as the skin or the lining of the digestive tract, are called **exocrine glands.** Glands that secrete their products into tissue fluid or blood are called **endocrine glands.** (Endocrine glands are discussed in chapter 13.)

An exocrine gland may consist of a single epithelial cell (unicellular gland), such as a mucous-secreting goblet cell, or it may be composed of many cells (multicellular gland). In turn, the multicellular forms can be structurally subdivided into two groups—simple and compound glands.

A *simple gland* communicates with the surface by means of a duct that does not branch before reaching the glandular cells or secretory portion, and a *compound gland* has a duct that branches repeatedly before reaching the secretory portion. These two types of glands can be further classified according to the shapes of their secretory portions. Glands that consist of epithelial-lined tubes are called *tubular glands;* those whose terminal portions form saclike dilations are called *alveolar glands* (acinar glands). Branching and coiling of the secretory portions

may occur as well. Figure 5.10 illustrates several types of exocrine glands classified by structure. Table 5.2 summarizes the types of exocrine glands, lists their characteristics, and provides an example of each type.

Exocrine glands are also classified according to the ways these glands secrete their products. Glands that release fluid products by exocytosis are called **merocrine glands.** Glands that lose small portions of their glandular cell bodies during secretion are called **apocrine glands.** Glands that release entire cells are called **holocrine glands.** After release, the cells containing accumulated secretory products disintegrate, liberating their secretions

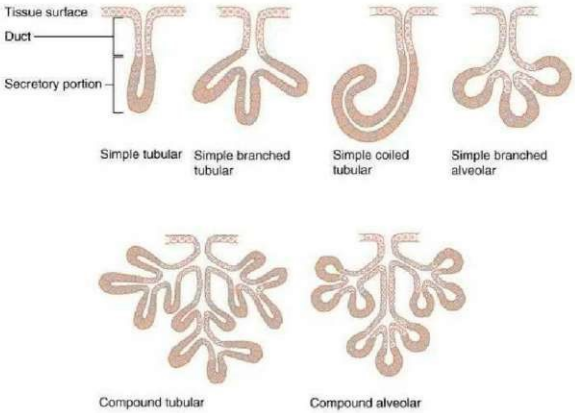

FIGURE 5.10
Structural types of exocrine glands.

TABLE 5.2 Types of Exocrine Glands

Type	Characteristics	Example
Unicellular glands	A single secretory cell	Mucous-secreting goblet cell (see fig. 5.3)
Multicellular glands	Glands that consist of many cells	
Simple glands	Glands that communicate with surface by means of ducts that do not branch before reaching the secretory portion	
1. Simple tubular gland	Straight tubelike gland that opens directly onto surface	Intestinal glands of small intestine (see fig. 17.3)
2. Simple coiled tubular gland	Long, coiled, tubelike gland; long duct	Eccrine (sweat) glands of skin (see fig. 6.9)
3. Simple branched tubular gland	Branched, tubelike gland; duct short or absent	Gastric glands (see fig. 17.19)
4. Simple branched alveolar gland	Secretory portions of gland expand into saclike compartments along duct	Sebaceous gland of skin (see fig. 5.12)
Compound glands	Glands that communicate with surface by means of ducts that branch repeatedly before reaching the secretory portion	
1. Compound tubular gland	Secretory portions are coiled tubules, usually branched	Bulbourethral glands of male (see fig. 22.1)
2. Compound alveolar gland	Secretory portions are irregularly branched tubules with numerous saclike outgrowths	Mammary glands (see fig. 23.30)

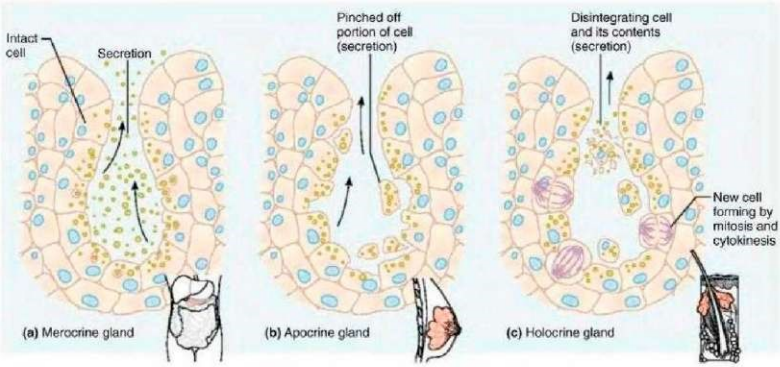

FIGURE 5.11
Glandular secretions. (*a*) Merocrine glands release secretions without losing cytoplasm. (*b*) Apocrine glands lose small portions of their cell bodies during secretion. (*c*) Holocrine glands release entire cells filled with secretory products.

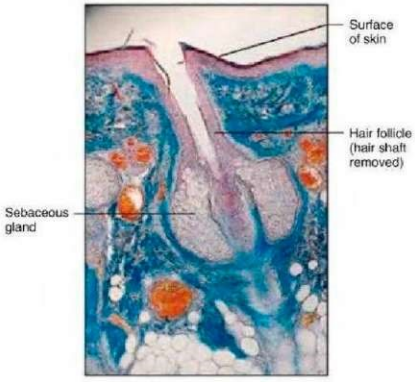

FIGURE 5.12
The sebaceous gland associated with a hair follicle is a simple branched alveolar gland that secretes entire cells (30×).

TABLE 5.3 Types of Glandular Secretions

Type	Description of Secretion	Example
Merocrine glands	A fluid product released through the cell membrane by exocytosis	Salivary glands, pancreatic glands, sweat glands of the skin
Apocrine glands	Cellular product and portions of the free ends of glandular cells pinch off during secretion	Mammary glands, ceruminous glands lining the external ear canal
Holocrine glands	Entire cells laden with secretory products disintegrate	Sebaceous glands of the skin

(figs. 5.11 and 5.12). Table 5.3 summarizes these glands and their secretions.

Most exocrine secretory cells are merocrine, and they can be further subdivided as either *serous cells* or *mucous cells*. The secretion of serous cells is typically watery, has a high concentration of enzymes, and is called *serous fluid*. Such cells are common in the linings of the body cavities. Mucous cells secrete a thicker fluid *mucus*. This substance is rich in the glycoprotein *mucin* and is abundantly secreted from the inner linings of the digestive and respiratory systems. Table 5.4 summarizes the characteristics of the different types of epithelial tissues.

1. Describe the structure of each type of epithelium.
2. Describe the special functions of each type of epithelium.
3. Distinguish between exocrine and endocrine glands.
4. Explain how exocrine glands are classified.
5. Distinguish between a serous cell and a mucous cell.

TABLE 5.4 Epithelial Tissues			
Type	**Description**	**Function**	**Location**
Simple squamous epithelium	Single layer, flattened cells	Filtration, diffusion, osmosis, covers surface	Air sacs of lungs, walls of capillaries, linings of blood and lymph vessels
Simple cuboidal epithelium	Single layer, cube-shaped cells	Secretion, absorption	Surface of ovaries, linings of kidney tubules, and linings of ducts of certain glands
Simple columnar epithelium	Single layer, elongated cells	Protection, secretion, absorption	Linings of uterus, stomach, and intestines
Pseudostratified columnar epithelium	Single layer, elongated cells	Protection, secretion, movement of mucus and substances	Linings of respiratory passages
Stratified squamous epithelium	Many layers, top cells flattened	Protection	Outer layer of skin, linings of oral cavity, vagina, and anal canal
Stratified cuboidal epithelium	2–3 layers, cube-shaped cells	Protection	Linings of larger ducts of mammary glands, sweat glands, salivary glands, and pancreas
Stratified columnar epithelium	Top layer of elongated cells, lower layers of cube-shaped cells	Protection, secretion	Part of the male urethra and parts of the pharynx
Transitional epithelium	Many layers of cube-shaped and elongated cells	Distensibility, protection	Inner lining of urinary bladder and linings of ureters and part of urethra
Glandular epithelium	Unicellular or multicellular	Secretion	Salivary glands, sweat glands, endocrine glands

Connective Tissues

General Characteristics

Connective tissues (kō-nek'tiv tish'ūz) comprise much of the body and are the most abundant type of tissue by weight. They bind structures, provide support and protection, serve as frameworks, fill spaces, store fat, produce blood cells, protect against infections, and help repair tissue damage.

Connective tissue cells are farther apart than epithelial cells, and they have an abundance of **extracellular matrix** (eks"trah-sel'u-lar ma'triks) between them. This extracellular matrix consists of fibers and a *ground substance* whose consistency varies from fluid to semisolid to solid. The ground substance binds, supports, and provides a medium through which substances may be transferred between the blood and cells within the tissue. Clinical Application 5.1 discusses the extracellular matrix and its relationship to disease.

Connective tissue cells can usually divide. These tissues have varying degrees of vascularity, but in most cases, they have good blood supplies and are well nourished. Some connective tissues, such as bone and cartilage, are quite rigid. Loose connective tissue (areolar), adipose tissue, and dense connective tissue are more flexible.

Major Cell Types

Connective tissues contain a variety of cell types. Some of them are called *fixed cells* because they reside in the specific connective tissue type for an extended period of time. These include fibroblasts and mast cells. Other cells, such as macrophages, are *wandering cells*. They move through and appear in tissues temporarily, usually in response to an injury or infection.

The **fibroblast** (fī'bro-blast) is the most common kind of fixed cell in connective tissues. These large, star-shaped cells produce fibers by secreting proteins into the extracellular matrix of connective tissues (fig. 5.13).

Macrophages (mak'ro-fājez), or histiocytes, originate as white blood cells (see chapter 14, p. 538) and are almost as numerous as fibroblasts in some connective tissues. They are usually attached to fibers but can detach and actively move about. Macrophages are specialized for phagocytosis. Because they function as scavenger cells that can clear foreign particles from tissues, macrophages are an important defense against infection (fig. 5.14). They also play a role in immunity (see chapter 16, p. 639).

Mast cells are large and are widely distributed in connective tissues, where they are usually located near

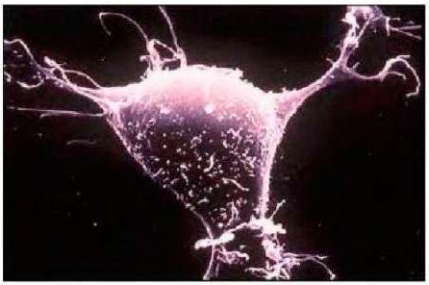

FIGURE 5.13
A scanning electron micrograph of a fibroblast (4,000×).